

# Noninvasive treatments for iatrogenic priapism: Do they really work? A prospective multicenter study

Mohamad Habous, Mohammed Elkhoully, Osama Abdelwahab<sup>1</sup>, Mohammed Farag<sup>2</sup>, Khaled Madbouly<sup>3</sup>, Talal Altuwajiri<sup>4</sup>, Marco Spilotros<sup>5</sup>, Carlo Bettocchi<sup>6</sup>, Saleh Binsaleh<sup>7</sup>

Department of Urology and Andrology, Elaj Medical Center, Jeddah, <sup>1</sup>Department of Urology, Benha University, <sup>2</sup>Department of Urology, Al-Azhar University, Egypt, Departments of <sup>3</sup>Urology and <sup>4</sup>Vascular Surgery, Prince Mohammed Bin Abdulaziz Hospital, Riyadh, Saudi Arabia, <sup>5</sup>Department of Urology, University College Hospital London, London, United Kingdom, <sup>6</sup>Department of Emergency and Organ Transplantation - Urology, Andrology and Kidney Transplantation Unit, University of Bari, Bari, Italy, <sup>7</sup>Department of Surgery, Division of Urology, Faculty of Medicine, King Saud University, Riyadh, Saudi Arabia

## Abstract

**Objectives:** Intracorporeal injections (ICIs) of vasoactive substances during penile Doppler ultrasound (PDU) are a common investigation for erectile dysfunction (ED) diagnosis. ICI can be responsible of priapism, a pathological condition of prolonged penile erection not related to sexual stimulation. The aim of our study is to investigate the effectiveness of physical exercise and medical treatment as noninvasive therapy to restore detumescence in prolonged erections after ICI.

**Materials and Methods:** Data were prospectively collected on men undergoing PDU in three urological centers. Three hundred and sixty-nine patients underwent PDU for the investigation of ED. All the participants received an ICI of quadrimix; prostaglandine E1, papaverine, phentolamine, and atropine. The data of the patients have been analyzed to record their comorbidities, results of PDU, and the complications encountered.

**Results:** Fifty-three patients (14.4%) developed prolonged erections. Physical exercise alone was successful in reversing prolonged erection within 30 min in 21 (39.6%) patients. Out of the remaining 32 patients, oral salbutamol induced detumescence in 18 (34%) within the observation period of 60 min. Nonresponders were managed successfully with aspiration and irrigation of corpora with saline (11 patients, 20.75%) or with Phenylephrine (three patients, 5.66%).

**Conclusions:** Physical exercise and oral salbutamol are safe and effective in restoring detumescence of pharmacologically-induced priapism. Noninvasive therapy may save a significant number of these patients an invasive treatment.

**Key Words:** Conservative therapy, erectile dysfunction, exercise, noninvasive, priapism

### Address for correspondence:

Dr. Saleh Binsaleh, Department of Surgery, Faculty of Medicine, King Saud University, P. O. Box 36175, Riyadh 11419, Saudi Arabia.  
E-mail: binsaleh@ksu.edu.sa

**Received:** 05.12.2015, **Accepted:** 08.01.2016

### Access this article online

#### Quick Response Code:



#### Website:

www.urologyannals.com

#### DOI:

10.4103/0974-7796.176874

This is an open access article distributed under the terms of the Creative Commons Attribution-NonCommercial-ShareAlike 3.0 License, which allows others to remix, tweak, and build upon the work non-commercially, as long as the author is credited and the new creations are licensed under the identical terms.

**For reprints contact:** reprints@medknow.com

**How to cite this article:** Habous M, Elkhoully M, Abdelwahab O, Farag M, Madbouly K, Altuwajiri T, *et al.* Noninvasive treatments for iatrogenic priapism: Do they really work? A prospective multicenter study. *Urol Ann* 2016;8:193-6.

## INTRODUCTION

Penile Doppler ultrasound (PDU) is a common investigation for the diagnosis of erectile dysfunction (ED). The response to intracorporeal injections (ICIs) of vasoactive substances during this procedure represents a useful tool to evaluate arterial and veno-occlusive function.<sup>[1,2]</sup> Vasoactive regimens commonly include alprostadil alone prostaglandine E1 (PgE1) but formulations based on phentolamine, chlorpromazine, papaverine, and atropine can be used in selected cases.<sup>[3,4]</sup>

Priapism, a pathological condition of prolonged penile erection not related to sexual stimulation, can follow ICI in 2–18% of patients depending on the pharmac stimulation adopted.<sup>[5,6]</sup> In papaverine/phentolamine/alprostadil ICI programs prolonged erections have been reported in 5–35% of patients.<sup>[7]</sup>

The recommended initial treatment of ischemic priapism is the decompression of the corpora cavernosa by aspiration, followed, if unsuccessful, by  $\alpha$ -adrenergic injection or irrigation.<sup>[8]</sup> Some historical reports advised voiding and exercise.<sup>[7]</sup> Oral sympathomimetic drugs (etilefrine, pseudoephedrine, phenylpropanolamine, and terbutaline) have been reported to effectively reverse prolonged erection (>4 h) initiated by intracavernous injection therapies with efficacies of 28–36%.<sup>[6,9]</sup>

In this study, we evaluate our experience in management of post ICI iatrogenic priapism with special emphasis on the role of noninvasive interventions; physical exercise and medical treatment, in the restoration of penile detumescence.

## MATERIALS AND METHODS

From September 2012 to February 2014, 369 patients underwent PDU in three urological centers participating in the current study. Those patients underwent PDU as part of their investigational work up for ED. Complete medical history and thorough physical examination were done for all participants. Blood investigations were performed to assess patients' hormone levels, blood glucose, and lipid profile.

The records of the patients have been analyzed to record their comorbidities, results of PDU, and the complications encountered.

Each patient received intracavernosal injection of 0.3 mL freshly prepared Quadrimix solution (PgE1 5  $\mu$ g/mL, papaverine 15 mg/mL, phentolamine 1 mg/mL, and atropine 20 mcg/mL).

PDU was performed in a quiet, air-conditioned room with a restricted number of operators to avoid psychological influences

and reduce false positive results. The evaluation was performed before injection and 10 min after being left alone in the room and invited to perform a genital self-stimulation so that the last evaluation is performed with the higher degree of erection.

At the end of the procedure, all the patients were observed till complete detumescence occurred. Patients who showed prolonged erection more than 3 h were asked to walk up and down a flight of stairs for 30 min. If prolonged erection still persisted at the end of this period, salbutamol 4 mg (2 tablets) was given orally, and erection was observed for 60 min. Patients' blood pressure and pulse rate were monitored during this period. Failure to respond to salbutamol within 60 min was followed by an intracorporeal aspiration and irrigation with phenylephrine. A transcavernosal 18-Gauge needle was placed percutaneously into the lateral aspect of the proximal penile shaft. Aspiration and evacuation of blood from the corpora cavernosa were performed with irrigation of normal saline followed by irrigation with phenylephrine (200  $\mu$ g/mL) in saline and administered intermittently as 1.0 mL, every 3–5 min to a maximum dosage of 1 mg. Vital signs were checked before and for an hour after the injection with phenylephrine. No shunt procedure was necessary in any patient. An informed consent was collected from all participants, and the study was approved by the Local Institutional Ethics Committee.

## RESULTS

Out of the 369 patients reviewed, 53 (14.4%) developed prolonged erections. The average age of the patients was 43.1 (range: 26–61) years. The etiology of ED for patients with prolonged erection was vasculogenic in 39 (73.6%), psychogenic in 7 (13.2%), and hormone-related in 7 (13.2%).

Associated comorbidities included obesity in 35 patients (66%; body mass index 27–43), diabetes in 17 (32%), and hypertension in 6 (11.3%).

Physical exercise alone was successful in reversing prolonged erection within 30 min in 21 (39.6%) patients. Out of the remaining 32 patients, oral salbutamol induced detumescence in 18 (34%) within the observation period of 60 min. In the 14 patients (26.41%) who failed to respond to previous attempts, aspiration and irrigation of corpora with saline solution through an 18-Gauge needle resulted in an immediate and stable detumescence in 11 (20.75%). Three patients (5.66%) failed to achieve detumescence with the aspiration and irrigation and further irrigation with Phenylephrine was performed and was successful in all of them. No patient required surgical intervention. Monitoring of vital signs showed no significant tachycardia or blood pressure changes throughout the observation period.

The study flow chart and number of the patients in each step are demonstrated in Figure 1.

**DISCUSSION**

Priapism, a prolonged erection not related to sexual stimulation, can be caused by intracorporal injections of vasoactive agents used during PDU.<sup>[5,6]</sup> Low flow or ischemic priapism is characterized by a reduced venous outflow, hypoxia, rising CO<sub>2</sub>, and acidosis and if untreated can cause irreversible injury and necrosis to the erectile tissue with consequent fibrosis of the corporas.<sup>[7,10,11]</sup>

Corporal aspiration and irrigation with warm or cold saline and sympathomimetics are the recommended treatment of ischemic priapism to decompress the corpora cavernosa and should precede shunt surgery.<sup>[7,8,12]</sup>

Although some historical reports are existing about physical exercise in relieve of priapism,<sup>[7]</sup> its effectiveness has never been evaluated formally in the recent literature. In our study, physical exercise alone reversed prolonged erection in 21 (39.6%) patients.

Our study clearly suggests the efficacy of oral salbutamol, a β<sub>2</sub> adrenergic receptor agonist in relieve of drug-induced prolonged erection. Salbutamol effectively induced detumescence within the observation period of 60 min in 18 out of 32 patients who failed physical exercise. No significant tachycardia or blood pressure changes have been encountered in our patients.

Oral treatment with terbutaline and pseudoephedrine or local injection of Etilefrine can be used as the first-line approaches to control prolonged erections if administered early <4 h of its onset.<sup>[9,13,14]</sup>

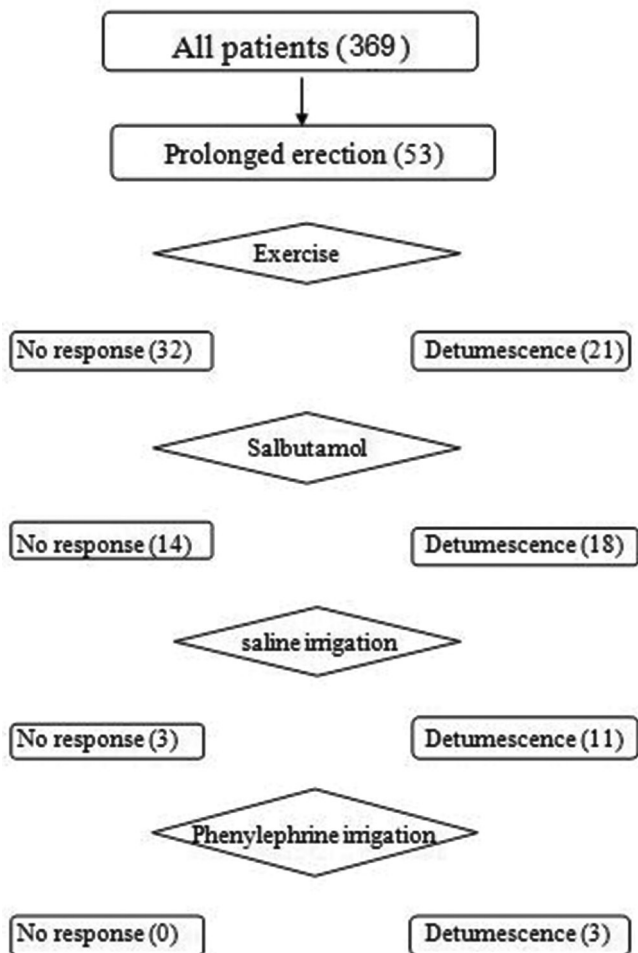
Although oral salbutamol was not previously evaluated in the literature, terbutaline, a synthetic sympathomimetic, β<sub>2</sub> agonist with minor β<sub>1</sub> effects has been extensively evaluated.<sup>[6,15]</sup>

Lowe and Jarow<sup>[9]</sup> compared oral terbutaline with pseudoephedrine or placebo in 75 patients with prolonged erection induced by intracavernous injection of alprostadil. They reported detumescence in 38% of cases following terbutaline, 28% following pseudoephedrine, and 12% following placebo.

In a study by Priyadarshi,<sup>[6]</sup> the efficacy of oral terbutaline in the management of prolonged erection following intracavernous injections (papaverine/chlorpromazine) was evaluated. Patients with persisting erection for more than 2.5 h were randomized into two groups, 34 patients each. Detumescence was achieved in 14 and five patients, respectively, treated with terbutaline and placebo. The difference was statistically significant. Parenteral terbutaline has also been successfully used in the treatment of intraoperative penile erection.<sup>[16]</sup>

The mechanism of action of terbutaline in causing penile detumescence has not been clearly elucidated. The cavernous smooth muscles are not only mechanically stretched due to rapid filling of blood, but they contract (like a stretched spring) against the blood providing rigidity. Terbutaline probably acts by relaxation of the stretched corporeal smooth muscles, relaxation of polsters in the penile veins, widening of the diameter of the corporeal draining veins, and removal of the impediment of venous blood flow created by contracting polsters resulting in penile flaccidity.<sup>[17]</sup> Detumescence due to β<sub>2</sub> agonist may also be due to increased permeability of erectile cavernous tissue permitting easy flow of fluid from sinusoids into the venous system.<sup>[6]</sup> However, terbutaline is given cautiously in patients with coronary artery disease, increased intravascular fluid volume, pulmonary edema, and hypokalemia.<sup>[18]</sup>

Overall, of the 53 patients who developed prolonged erections in our study, 39 (73.6%) responded well to noninvasive therapy (physical exercise and oral salbutamol treatment).



**Figure 1:** Patients' flowchart

Our study is reintroducing the role of physical exercise in the management of priapism into the current literature so that its role and effectiveness could be further evaluated. Furthermore, oral medical therapy of pharmacologically-induced prolonged erections is more attractive than invasive procedures. Oral medical therapy can be self-administered at an earlier time at home. It obviates the need for an emergency visit to a hospital for intracorporeal Phenylephrine injection and its associated psychological sequelae.

Our findings showed that noninvasive therapy, including physical exercise and oral salbutamol, may save a significant number of patients with iatrogenic priapism invasive treatment. Most of our patients (73.6%) responded well to noninvasive therapy with no need for further treatment. Furthermore, oral therapy was safe, and none of our patients develop significant tachycardia or blood pressure changes.

Our study is limited by the involvement of a relatively low number of patients who are belonging only to the category of pharmacologically-induced priapism, thus our results cannot be extrapolated to other priapism patients. The dose of quadrimix used in the study was a fixed non titratable one (0.3 mL) which by itself may be the reason behind the high incidence of iatrogenic priapism (14.4%) in our study group.

## CONCLUSIONS

Iatrogenic priapism after ICI with vasoactive agents is not uncommon complication. In our series, physical exercise and oral treatment with a  $\beta^2$  adrenergic agonist were safe and effective in restoring detumescence in most of the pharmacologically-induced priapism patients. Noninvasive therapy is worthwhile and should be tried as a first line therapy before submitting those patients to more invasive therapy.

## Financial support and sponsorship

This study was supported by a grant from the College of Medicine Research Center, Deanship of Scientific Research, King Saud University, Riyadh, Saudi Arabia.

## Conflicts of interest

There are no conflicts of interest.

## REFERENCES

- Mueller SC, Lue TF. Evaluation of vasculogenic impotence. *Urol Clin North Am* 1988;15:65-76.
- Altinkilic B, Hauck EW, Weidner W. Evaluation of penile perfusion by color-coded duplex sonography in the management of erectile dysfunction. *World J Urol* 2004;22:361-4.
- Nisén H, Cormio L. Pharmacotesting with high dose prostaglandin E1 in impotence. *Ann Chir Gynaecol Suppl* 1993;206:63-8.
- Seyam R, Mohamed K, Akhras AA, Rashwan H. A prospective randomized study to optimize the dosage of trimix ingredients and compare its efficacy and safety with prostaglandin E1. *Int J Impot Res* 2005;17:346-53.
- Lomas GM, Jarow JP. Risk factors for papaverine-induced priapism. *J Urol* 1992;147:1280-1.
- Priyadarshi S. Oral terbutaline in the management of pharmacologically induced prolonged erection. *Int J Impot Res* 2004;16:424-6.
- Broderick GA, Kadioglu A, Bivalacqua TJ, Ghanem H, Nehra A, Shamloul R. Priapism: Pathogenesis, epidemiology, and management. *J Sex Med* 2010;7(1 Pt 2):476-500.
- Montague DK, Jarow J, Broderick GA, Dmochowski RR, Heaton JP, Lue TF, *et al.* American Urological Association guideline on the management of priapism. *J Urol* 2003;170(4 Pt 1):1318-24.
- Lowe FC, Jarow JP. Placebo-controlled study of oral terbutaline and pseudoephedrine in management of prostaglandin E1-induced prolonged erections. *Urology* 1993;42:51-3.
- Spycher MA, Hauri D. The ultrastructure of the erectile tissue in priapism. *J Urol* 1986;135:142-7.
- Broderick GA, Harkaway R. Pharmacologic erection: Time-dependent changes in the corporal environment. *Int J Impot Res* 1994;6:9-16.
- Ateyah A, Rahman El-Nashar A, Zohdy W, Arafa M, Saad El-Den H. Intracavernosal irrigation by cold saline as a simple method of treating iatrogenic prolonged erection. *J Sex Med* 2005;2:248-53.
- Tay YK, Spermat D, Rzetelski-West K, Appu S, Love C. Acute management of priapism in men. *BJU Int* 2012;109 Suppl 3:15-21.
- Keoghane SR, Sullivan ME, Miller MA. The aetiology, pathogenesis and management of priapism. *BJU Int* 2002;90:149-54.
- Soni BM, Vaidyanathan S, Krishnan KR. Management of pharmacologically induced prolonged penile erection with oral terbutaline in traumatic paraplegics. *Paraplegia* 1994;32:670-4.
- Shantha TR, Finnerty DP, Rodriquez AP. Treatment of persistent penile erection and priapism using terbutaline. *J Urol* 1989;141:1427-9.
- Goldstein AM, Meehan JP, Zakhary R, Buckley PA, Rogers FA. New observations on microarchitecture of corpora cavernosa in man and possible relationship to mechanism of erection. *Urology* 1982;20:259-66.
- Wheeler AS, Patel KF, Spain J. Pulmonary edema during beta-2-tocolytic therapy. *Anesth Analg* 1981;60:695-6.